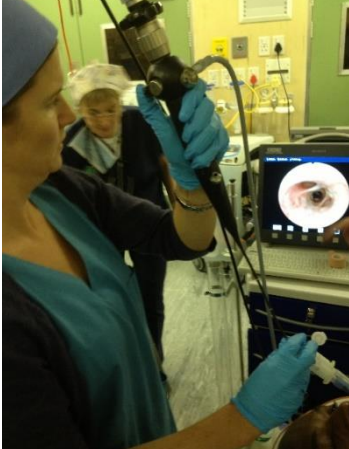
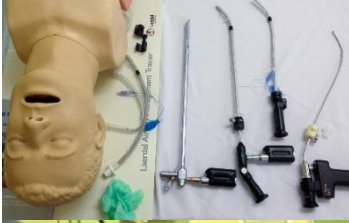
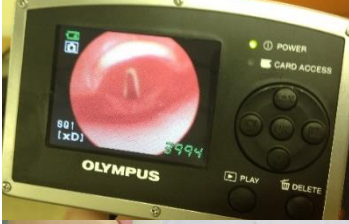
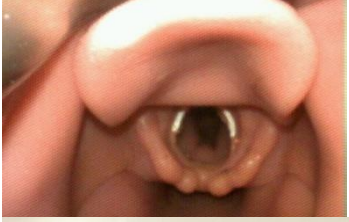
AEIOU

Airway Endoscopy for Intubation... and Other Uses

Workshop Manual, Second Edition, 2015

Department of Anaesthesia
University of Cape Town
Clinical Skills Laboratory
Groote Schuur Hospital

2015



OpenAirway



**DEPARTMENT OF
ANAESTHESIA**
UNIVERSITY OF CAPE TOWN

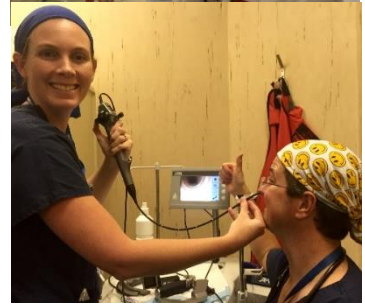
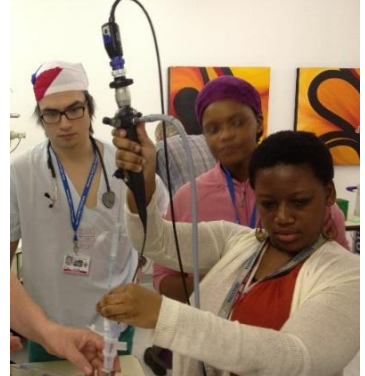
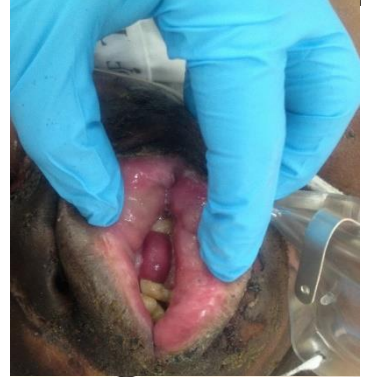
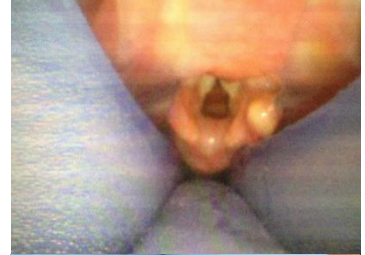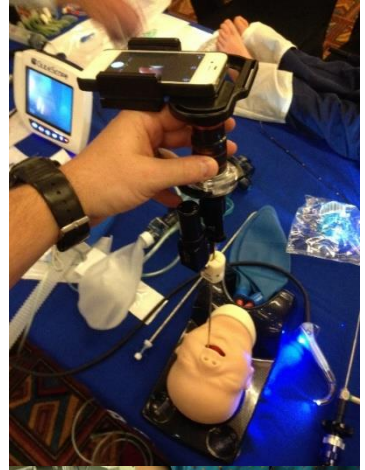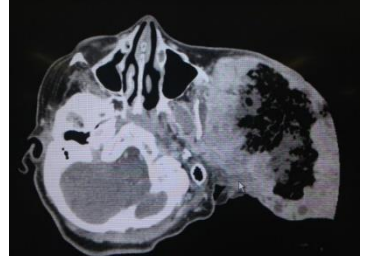Table of Contents

Title page.....	1
Programme	3
Introduction	4
Contributors.....	5
Sponsors.....	5
Airway Anatomy and Endoscopy Tips.....	6
Equipment for Endoscopic Intubation	10
Types of airway endoscopes for intubation.....	10
Rigid intubating endoscopes.....	10
Flexible endoscopes.....	11
Care and cleaning.....	11
Rescuing the Airway: Rigid Bronchoscopy.....	12
Videolaryngoscopy: Strategies for Mastery.....	14
Balancing topicalization and sedation in AFOI.....	17
Psychological preparation facilitates the procedure.....	17
Adequate topicalization of the airway.....	17
Sedative agents.....	18
Practical Awake Flexible/Fibreoptic Intubation.....	19
Advantages of the awake state for flexible fibreoptic intubation.....	19
Definition of a difficult airway	19
Indications.....	20
The difficult airway with impending airway obstruction.....	20
Patients at risk of aspiration	20
Requirements for AFOI	21
The flexible bronchoscope.....	21
Nasal vs oral intubation	21
Airway Innervation.....	21
Nasal cavity	21
Oropharynx.....	21
Larynx.....	22
Anaesthetising the airway	22
Some techniques of airway anaesthesia.....	22
Topical anaesthesia.....	22
Airway nerve blocks.....	23
Antisialagogue	24

Sedation	24
Benzodiazepines	25
Propofol	25
Opioids	26
Conclusion on sedation.....	27
Supplemental oxygen.....	28
Complications of AFOI.....	28
Training	28
A stepwise approach to training would be as follows	28
A needle-free technique for nasal AFOI.....	29
References for this section	30
Appendix A – ASA Difficult Airway Algorithm	31
Appendix B – Precedex (Dexmedetomidine) AFOI Protocol.....	32
Appendix C – DAS FOI via SAD with Aintree Intubation Catheter	33
Appendix D – References.....	34

Programme

Start	Finish	Topic	Instructor
07h30	08h00	Registration & coffee	Hofmeyr
08h00	08h10	Welcome & Housekeeping	Hofmeyr
08h10	08h20	Airway anatomy and endoscopy tips	Edkins
08h30	08h50	Equipment (types, function, care)	Hofmeyr
08h50	09h10	Rescuing the airway with rigid bronchoscopy	Edkins
09h10	09h30	Videolaryngoscopy: strategies for mastery	Hofmeyr
09h30	09h45	Questions/panel discussion	All
09h45	10h00	Tea	
10h00	12h30	Skills Stations:	
		Station 1: VL Masterclass	Hofmeyr
		Station 2: BronchoBoy - anatomy and dexterity	Alberts/Veronese
		Station 3: Dexter - anatomy and dexterity	Brennan/Visser
		Station 4: Rigid bronch & intubating endoscopes	Edkins/Prempeh
		Station 5: Endoscopic intubation through SGAs	Duys
12h30	13h30	Lunch	
13h30	13h50	Practical awake fiberoptic intubation	Brennan
13h50	14h15	Balancing topicalisation and sedation	Alberts
14h15	16h15	Skills Stations (minimum of 5)	All
		Airway topicalisation & endoscopy of participants	
		Mannequins available for extra practice/demo	
16h15	16h30	Wrap-up & closure	Hofmeyr

Introduction

Mastery of airway assessment and management remains a key area of knowledge and core skill for anaesthetists at all levels. The specialist anaesthesiologist is expected to have a commanding grasp of the majority of airway devices and techniques, and should be intimately familiar with dealing with airway emergencies. It is essential to become adept with the use of airway rescue devices and techniques in the non-emergency situation, before such skill is required in anger.

Airway equipment continues to develop along several themes, with new devices appearing with a regularity only matched by the paucity of good quality evidence about their clinical efficacy. Adequate comparative data frequently takes years to emerge. Anaesthesiologists, particularly those involved in equipment procurement, should familiarise themselves with the medical (not marketing) literature, and the suggested guidelines for device assessment.¹

Algorithms for airway rescue and the management of anticipated difficulty continue to be developed and renewed. The major national and professional anaesthesia societies release updated algorithms in a roughly 5 year cycle, which are usually to be found on their respective webpages. The Difficult Airway Society (DAS)² and Vortex³ (see below) guidelines are useful for study and reference in theatre. The 2015 DAS guideline update is anticipated in November 2015. SASA's most recent version was published 2014 and distributed in March 2015.⁴ It includes lists of recommended equipment for all levels of care. Significant trends in the various guidelines include:

- Early use of video laryngoscopes where suitable skill exists
- Including the use of VL as an initial plan in anticipated difficulty
- Emphasis on supraglottic airways (SGAs) as rescue devices in failed intubation
- SGAs for cardiac resuscitation to minimise interruptions of chest compressions
- A move from referring to CICV (can't intubate, can't ventilate) to the more focused CICO (can't intubate, can't oxygenate) nomenclature
- Planning of multiple strategies (Plan A, B, C etc.) before commencing airway management.

An updated collection of airway algorithms from various sources (ASA, DAS, Vortex, SASA, etc.) can be found at www.openairway.org/algorithms

Regardless of which algorithm is consulted, the gold standard for the management of predicted severe airway difficulty is the use of airway endoscopy to perform intubation. While video laryngoscopes continue to increase their usefulness and role, both flexible and rigid intubating endoscopes remain critical tools in the armamentarium of the airway master. The skill to operate these devices effectively, however, requires a high level of training and practice, and a fundamental understanding of the function, strengths, weaknesses and ideal applications of each type.

The AEIOU workshop is designed to give both novice and experienced practitioners the opportunities to expand their hands-on skill with all forms of airway endoscopy. We aim to achieve this through brief and targeted lectures which supplement maximum skills training time on both manikins and live patient models.

Your engagement and interaction during the course, and feedback upon its conclusion will assist us in improving the education we can provide in future.

Contributors

To remain current and relevant, any academic document should remain away; this is certainly true of this manual. We are indebted to the faculty and instructors on the course for providing a wealth of material which contained herein. The following individuals deserve credit for the production of this foundation for the inaugural AEIOU course:

- Dr Oskar Edkins, for his elucidation of airway anatomy and rigid bronchoscopy skills
- Prof Andrie Alberts, for his incisive assessment of the roles of topical as a sedation
- Dr Brigid Brennan, for her expansive and practical description of how to perform awake fiberoptic intubation
- The entire course instructors selflessly committing the time and expertise sharing knowledge.

We are exceptionally grateful to the University of Cape Town, and in particular the UCT clinical skills laboratory, for their ongoing and wholehearted support.

“The only way to truly take ownership of knowledge is to freely give it away.”

Dr Ross Hofmeyr
August 2015

Sponsors

Workshops of this calibre would not be able to be held without the strong academic backing of the Department of Anaesthesia at the University of Cape Town, and the excellent technical and financial support of the companies providing their equipment for our learning. We would like to give particular thanks to the following institutions and companies for their ongoing investment in clinical education:

abbvie

Dräger



DEPARTMENT OF
ANAESTHESIA
UNIVERSITY OF CAPE TOWN

STORZ
KARL STORZ—ENDOSKOPE

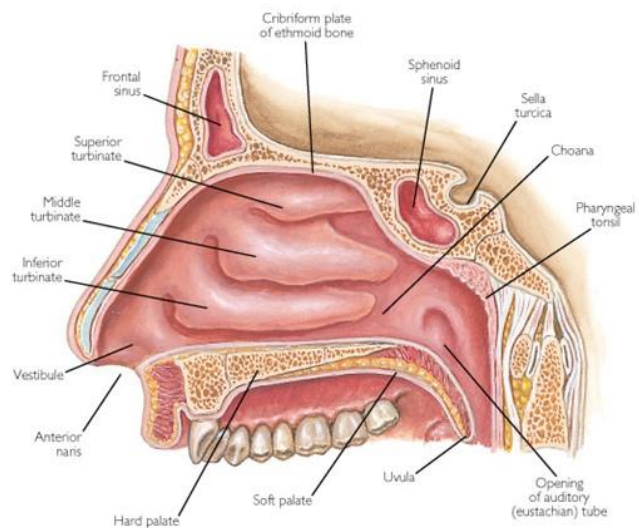
Teleflex

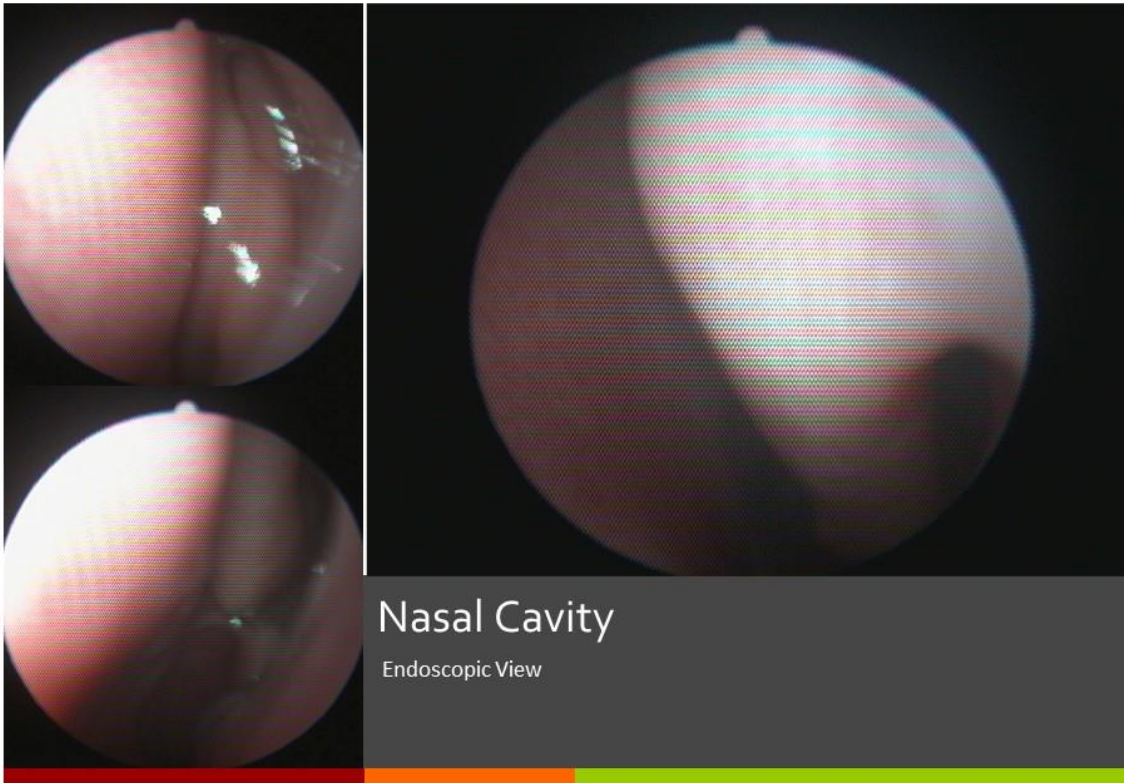
Anatomy

- Nasal Cavity
- Nasopharynx
- Pharynx, Hypopharynx & Larynx

Nasal Cavity

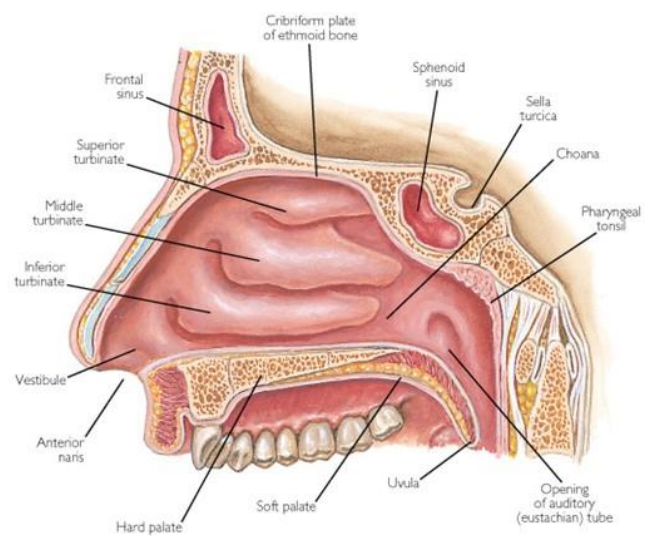
- Turbinates
 - Inferior
 - Middle
- Septum
- Floor





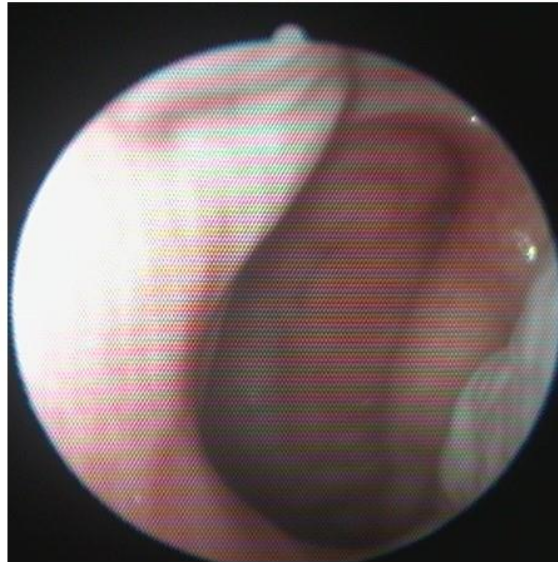Nasopharynx

- Choana
- Post Nasal Space
- Eustachian Tubes
- Soft Palate



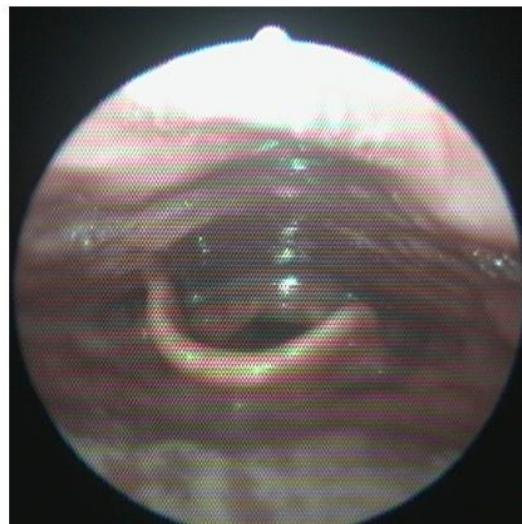
Nasopharynx

- Choanae
- Post Nasal Space
- Eustachian Tubes
- Soft Palate



Pharynx & Hypopharynx

- Tongue base
- Valecula
- Epiglottis
- Arytenoids
- Piriform fossae



Awake Fibre Optic Intubation - Tips

- Local Anaesthetic
 - Nasal Cavity – Atomiser + decongestant
 - Larynx – through scope under direct vision
- Pass flexible bronchoscope first to visualise larynx
 - Nasal ETT pre-loaded over scope
- Avoid misting of the scope
 - Warm water
 - Alcohol swab
 - Touch against Inferior turbinate in nose
 - Get patient to swallow in oropharynx



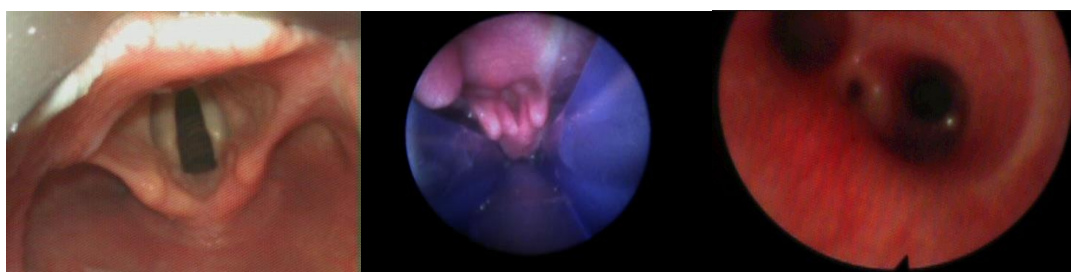
Rigid bronchoscopes

Equipment for Endoscopic Intubation

Dr Ross Hofmeyr
African Airway & Thoracic Anaesthesia Fellow
University of Cape Town

Types of airway endoscopes for intubation

Equipment for airway endoscopy can be divided into video laryngoscopes, and endoscopes designed to be placed through an endotracheal tube. Examples of the latter class are flexible fibre-optic bronchoscopes (or flexible intubating video endoscopes) and rigid intubating endoscopes such as the Bonfils or Shikani Optical Stylet. The video laryngoscopic devices (and similar optical laryngoscopes) are described in the separate section on video laryngoscopy. There are also devices which incorporate video endoscopy into intubating laryngeal masks, such as the CTrach and the TotalTrack VLM.



Endoscopic views of the airway. Left to right: video laryngoscope, rigid endoscope through supraglottic airway, flexible video endoscope.

Rigid intubating endoscopes

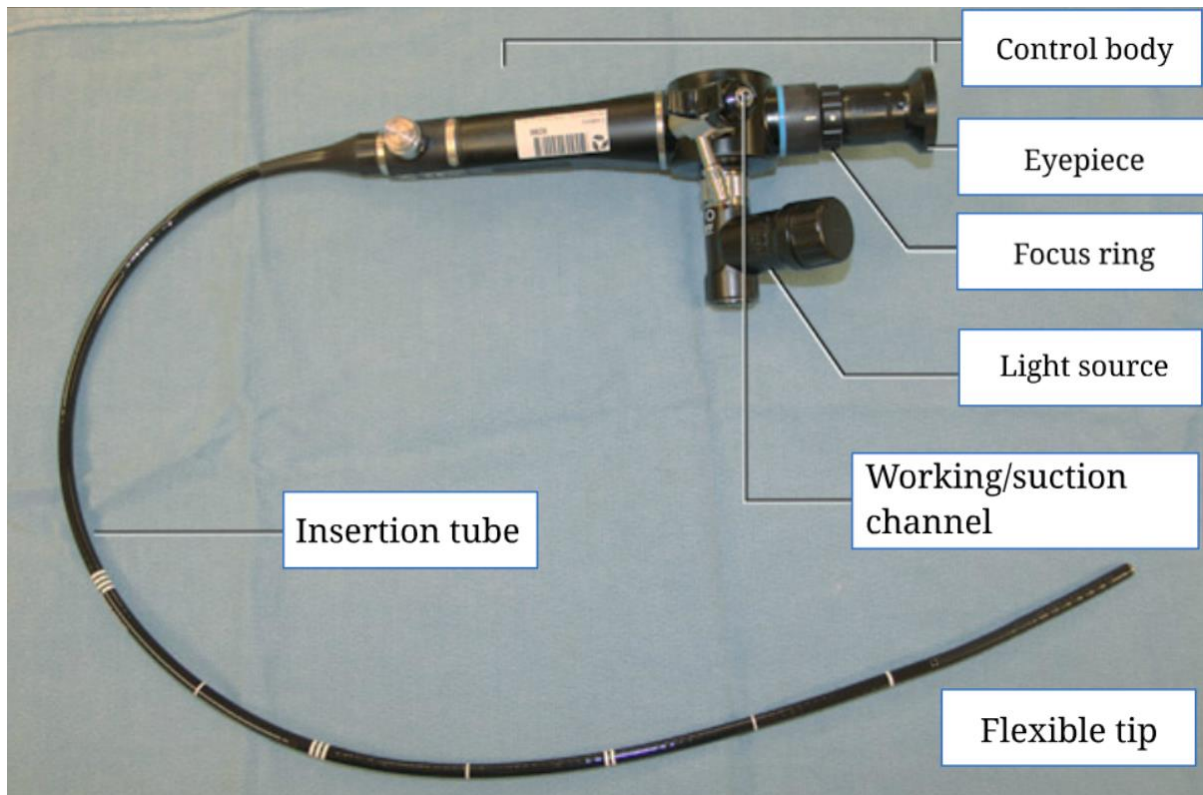
Rigid intubating endoscopes are designed to put inside an endotracheal tube, with the tip of the scope just behind the tip of the tube. This allows a view through the device during intubation. Two techniques can be used: midline, and retromolar. For the midline technique, one hand lifts jaw, or a normal direct laryngoscope is used, which aids difficult intubation where there is limited view of the vocal cords or even epiglottis. In patients with limited mouth opening, or obstructions of the floor of the mouth (such as tumours or submandibular abscess), a retromolar technique can be employed, whereby the scope is passed posteriorly to the molars from the side of the mouth, and is brought into the midline from an oblique angle. Rigid intubating endoscopes are not designed to be passed beyond the vocal cords, but rather to obtain a view of the glottic opening and then allow the tube to be slide of into the trachea.



Bonfils (left) and Clarus (right) rigid intubating endoscopes

Flexible endoscopes

Flexible 'scopes can be either designed for bronchoscopy, or as dedicated flexible intubating endoscopes. They are divided into the fibreoptic endoscopes, such as the well-known flexible fibreoptic bronchoscope (FOB), and video endoscopes, where an LED light source "chip-in-tip" video camera are used to give light and create an image, in place of the fibreoptic bundles used to transmit light and image in a fibreoptic bronchoscope. Because video intubating endoscopes do not contain the delicate fibreoptic bundles, they tend to have a larger working channel and be more robust. However these devices are still delicate pieces of equipment which require very careful care and cleaning.



Features of a modern flexible fibreoptic intubating endoscope or bronchoscope

Care and cleaning


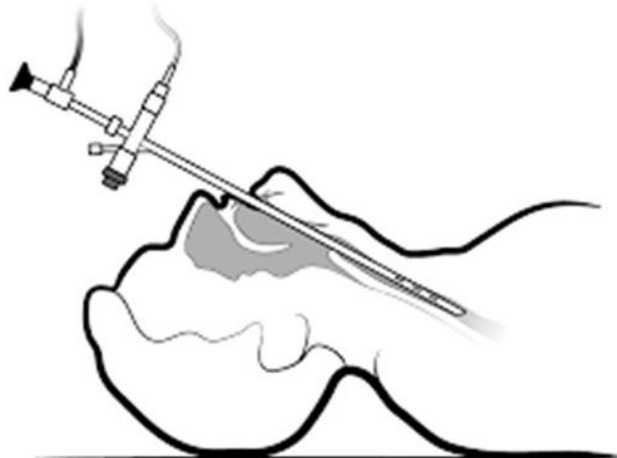
Cleaning and disinfection of endoscopes is a frequent cause of damage. In this setting, the rigid intubating scopes perform much better, as they are far more robust than any type of flexible 'scope. Flexible 'scopes need to be flushed carefully by suctioning a large quantity of warm water or saline through their working channel, wiped clean, and then be placed in an enzymatic detergent to break down any protein build-up or blood clots that may have formed. Thereafter, they are rinsed again and sterilised briefly in a sterilising solution such as Medis. Most hospitals have an infectious disease control protocol which describes the cleaning process for their 'scopes, and information on this process is also available with recommendations from the various manufacturers.

<http://www.entdev.uct.ac.za/guides/open-access-atlas-of-otolaryngology-head-neck-operative-surgery/>

Rigid Bronchoscopy

➤ Equipment

- At least 2 sizes of rigid bronchoscopes
- Components
 - Light carrier
 - Glass eyepiece
 - Instrument guide
 - Jet ventilation cannula
- Light source
- Appropriate size suction cannulas



Bronchoscope & Components

- A – Glass eyepiece
- B – Light Carrier
- C – Instrument guide / Jet ventilation adaptor
- D – Ventilator adaptor

Technique – Finding the Larynx & VC's

- Select largest suitable bronchoscope
- Positioning – intubation / sniffing the air
- Introduce scope in midline in vertical position, long bevel anteriorly
- Sliding scope over thumb / dental guard
- Identify uvula
- Advance scope in midline and identify epiglottis

Technique – Finding the Larynx & VC's

- Lift epiglottis anteriorly with long beveled tip of scope
- Identify posterior laryngeal inlet – arytenoids and posterior VC's
- Tips:
 - Hopkins rod inside bronchoscope
 - Elevate epiglottis with laryngoscope

Technique – Passing between the VC's

- Remove pillow and extend the patients head
- Rotate the scope through 90° keeping the longer beveled edge to the right
- Advance the scope with the tip of the bevel directed between the VC's
- Slide shorter edge along left VC
- Rotate scope back through 90° when into trachea

Technique – Passing between the VC's

- Tips:
 - Sit down on a mobile chair
 - Avoid traumatizing the right VC with the long bevel
 - Long bevel can be used to “core” through a tumour
 - Identify the carina
- Ventilate through bronchoscope
- Pass a bougie through scope, remove the scope and pass ET Tube over bougie

Videolaryngoscopy: Strategies for Mastery

Dr Ross Hofmeyr
African Airway & Thoracic Anaesthesia Fellow
University of Cape Town

Without doubt, the greatest area of development of new airway rescue tools over the last decade has been in the field of indirect laryngoscopy. Although several novel and effective optical laryngoscopic devices exist (eg. the AirTraq and Bonfils), the rapid improvement and decrease in cost of miniature video camera chips and LED light sources (fuelled by the smartphone industry) has led to an explosion of video laryngoscopes (VLs). At least 13 manufacturers exist at the time of writing:

- Glidescope – various iterations (original, GVL, AVL, Ranger, Cobalt, Titanium)
- Storz C-MAC – numerous blades available (MAC 2-4, MIL 0-2, D-blade)
- McGrath – Series 5, McGrath MAC with multiple blades
- King Vision – disposable ducted and plain blades
- AirTraq – Optical laryngoscope now offering a video attachment
- TrueView – Optical laryngoscope which has a camera attachment
- Pentax AWS – ducted VL with disposable blades
- Intubrite VLS – VL with LEDs designed to cause fluorescence of the vocal cords
- VividTrac VL – ‘Plug&Play’ disposable USB VL, not yet supported in SA
- CoPilot VL – Not yet supported in SA
- AP Advance VL – Not yet supported in SA
- Coopdech VLP – Not yet supported in SA
- Anatech Disposable VL – Not yet supported in SA
- Numerous other rather dubious copies and untested devices are available online...

The most recent devices in the South African market are the King Vision, McGrath MAC and Intubrite VL. The Glidescope Titanium series blades may be available before the end of 2015.

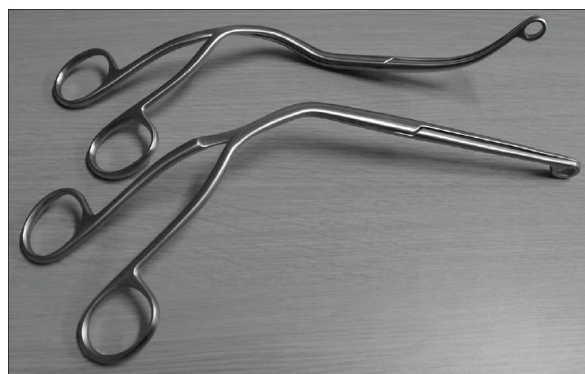

Video laryngoscopes. Top to bottom, left to right: Storz C-MAC, King Vision, McGrath MAC, Glidescope Cobalt, Pentax AWS, selection of Airtraq sizes, CoopTech VL, CoPilot VL

It is beyond the scope of these notes to try and compare the features and evidence behind all these devices. The Glidescope, C-MAC and AirTraq have the best breadth and depth of literature describing their use. However, it is helpful for the practitioner to understand the fundamental principles and function of the major classes of VL. If the optical/video stylets are omitted, there are 3 basic blade shapes, which determine the strengths, weaknesses and appropriate technique for each VL. Blades can either be traditional deeply curved/hyper-angulated or feature a tube guide channel/duct and close to 90° bend. The following table describes the important considerations.

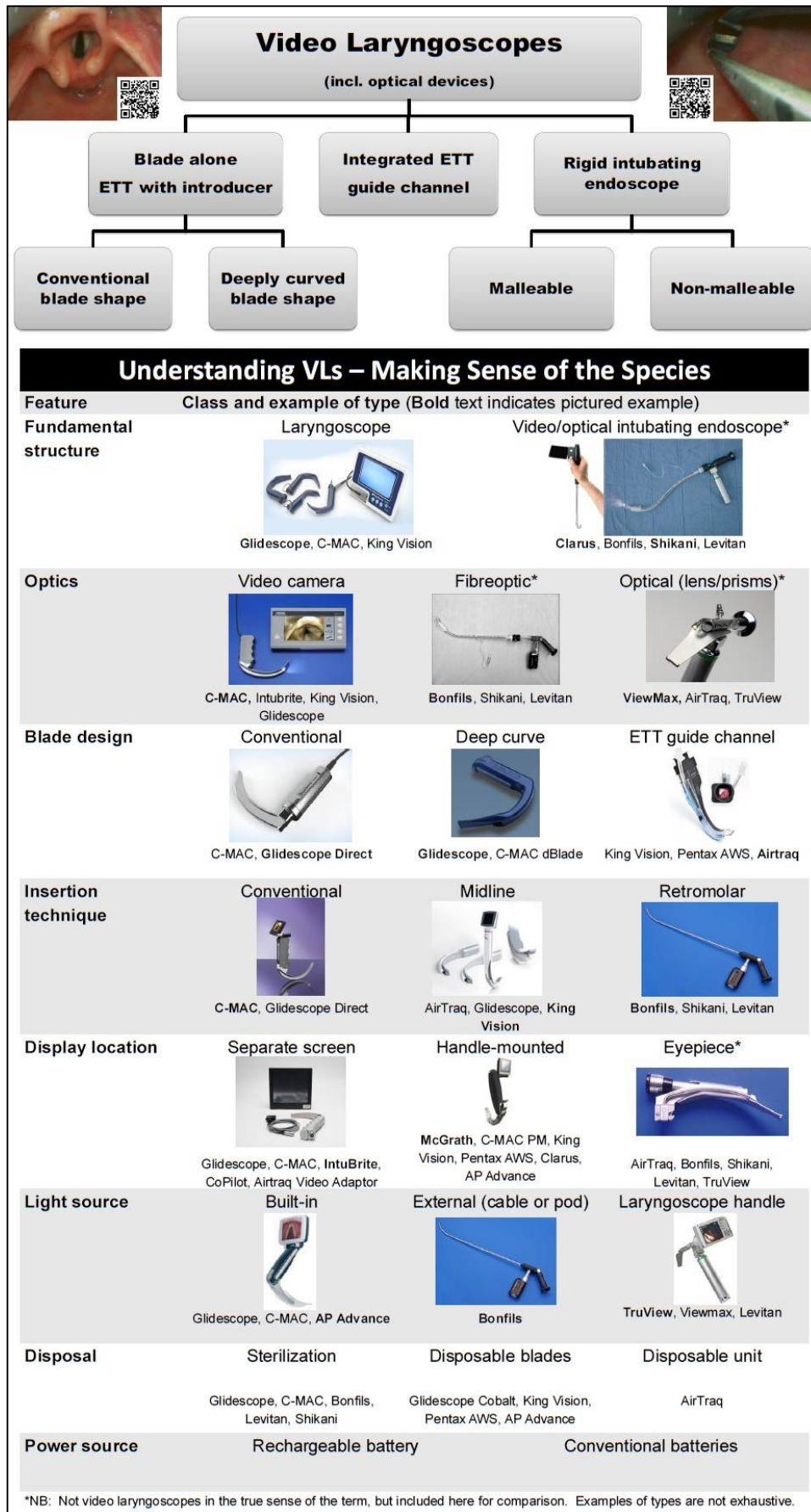Blade shape	Traditional	Hyper-angulated	Channelled/Ducted
Examples	Storz C-MAC Glidescope Direct TrueView Intubrite VL	Glidescope AVL Glidescope Titanium C-MAC D blade	Pentax AWS AirTraq King Vision
Insertion technique	Right side of mouth with subsequent tongue sweep (traditional technique)	Mostly in midline Devices with flange (C-MAC D) allow tongue sweep	Midline
Ideal uses	Routine VL use Anticipated difficulty without abnormal anatomy (eg. obesity) Teaching intubation	Anticipated difficulty Anatomical abnormalities Airways masses Failed DL	C-spine injury Airway swelling Novice VL users
Strengths	Short learning curve DL often possible May not require an introducer	Excellent visualisation in many airways that would otherwise require flexible fiberoptic intubation	Easiest to co-ordinate aim of tube (aim with device) Minimal mouth opening required
Weaknesses	Least advantage from video system	Require greatest skill Always require introducer	Can be awkward to insert due to length of device Tendency to insert too deeply
Ideal introducer	Any bougie with coude tip Malleable stylet in "hockey stick" shape	GlideRite stylet Malleable stylet in "hockey stick" shape Steerable introducers	Gum elastic bougie through endotracheal in channel
Ideal forceps	Magill	Boedeker ⁵ or Suzy ⁶ forceps	Not applicable

It is important to realise that any intubation performed by indirect laryngoscopy should be expected to require a device to guide the tube around the increase curvature of the airway. This may be an introducer, bougie or forceps. The ideal introducers/bougies for the various types of VL are detailed above. When using a hyperangulated VL blade, it may be necessary to use specially curved forceps.^{5, 6}



Shaped forceps (eg. Suzy or Boedeker) for use with video laryngoscopes, and standard Magill forceps.⁶

Intubating laryngeal masks have also been equipped with video capabilities to allow intubation through the SGA under indirect video laryngoscopy. The first device with this ability was the LMA-CTrach, a modification of the LMA-Fastrach which included a fiberoptic bundle and video display. Despite promising results, this device was withdrawn from the market.⁷⁻²¹ Recently, the TotalTrack VLM has been introduced. This device features a disposable intubating laryngeal mask coupled with a reusable video camera and display. Three clinical trials have been completed and are in press. The results of the first clinical trial by a South African group show success rates and efficacy rivalling that of the ILMA and CTrach, but further study is required.²²



Proposed classification of characteristics of indirect laryngoscopes.²³

AFOI is a procedure performed under topical anaesthesia. **Topicalization** therefore, is the key to the success of this procedure. Two additional interventions complete the triad required for successful AFOI. Pre-operative **psychological preparation** is aimed at recruiting and motivating an essential partner for the procedure. Cooperation from the partner is rewarded by judicious administration of **sedative agents**. The degree of reward is delicately balanced, with both under- and over-rewarding resulting in a loss of cooperation, and obstruction of the corporate aim.

Psychological preparation facilitates the procedure.

- a. Time must be set aside for meaningful communication; preferably on the day prior to the planned procedure. Do not hesitate to employ a translator if indicated.
- b. The patient's perception of empathy from the physician is the cornerstone of the patient's acceptance of an AFOI. It is imperative to describe (in a careful, unhurried manner) conventional intubation contrasted with AFOI, to the patient. (I.e. a detailed discussion of the procedure). The focus needs to be on the fact that AFOI is safer in view of the patient's own anatomy or condition. Most adult patients will appreciate an explanation of the need for an awake airway examination and intubation, and will be more cooperative once they realize the importance of, and rationale for, any uncomfortable procedures. I personally believe that a degree of frankness is required at some point; *"Sir, in view of your condition / anatomy we are faced with a serious problem relating to your anaesthetic scheduled for tomorrow. Your cooperation is absolutely essential"* much better sets the tone for a successful AFOI than a *"Don't worry, you won't feel a thing, you'll be halfway asleep, we'll see how it goes . . ."* approach. In a review of 443 cases of AFOI in which various combinations of sedation and analgesia were used, a mean of 17% of the patients had partial recall and only 6% had recall with unpleasant memories.

Adequate topicalization of the airway with local anaesthetics (LA) is the key to a successful AFOI

Topically applied LA attenuate the afferent limbs of the powerful reflexes that serve to protect the upper airway from aspiration of foreign material. A reduction in upper airway patency has been demonstrated following this loss of afferent feedback. Hence, care is needed when considering an awake airway management technique in a patient with evidence of upper airway narrowing. Lignocaine, given intravenously, likewise affects airway reactivity. Topical application of LA to the airway is unlikely to cause systemic toxicity, although the safe maximum dose is uncertain. Case reports of toxicity from topical use are rare. The British Thoracic Society recommendation for the use of topical lignocaine with a flexible fiberoptic bronchoscope in adults is not to exceed 8.2mg/kg. Sympathomimetics and antimuscarinics are often used in combination with LA.

- c. Sympathomimetics, such as adrenaline and phenylephrine, cause local vasoconstriction minimizing tissue vascularity, and reducing oedema. Topical vasoconstrictors such as adrenaline – administered via a nebulizer – can also

be used to minimize systemic absorption of topical LA (reducing toxicity), improve efficacy, and increase duration of action.

- d. Antimuscarinics, such as glycopyrrolate, inhibit the parasympathetic nervous system to reduce salivary gland secretions and dry the upper airway. Glycopyrrolate is devoid of central nervous system effects because its quaternary amine structure prevents passage through the blood-brain barrier. Its pharmacological profile makes it the drug of choice as an antimuscarinic premedicant for AFOL.

Sedative agents represent the grip or hold we have on delicately maintaining (balancing) patient cooperation throughout the procedure.

Sedation should generally be a supplement to, rather than a substitute for, topical anaesthesia of the airway. Even the slightest degree of *over- or under-dosing* may lead to a loss of patient comfort, a loss of cooperation, and failure of the procedure (or worse, should upper airway obstruction occur). The appropriate dose of sedative agent is determined by judging patient comfort and cooperation;

- a. **Patient comfort** – clinically this is achieved through analgesia, amnesia, and anxiolysis
- b. **Patient cooperation** – clinically this implies patient responsiveness to verbal command

Although almost any sedative agent can be used, some rules should apply to all;

- a. judicious dosing (primarily based on continuous patient cooperation i.e. responsiveness to verbal command)
- b. avoid polypharmacy (no more than two agents)
- c. have reversal agents at hand

An appreciation of the effects of sedative agents on the upper airway is crucial to the practice of safe airway management. There is a decrease in muscle tone associated with the loss of wakefulness, and this is compounded by specific drug-induced inhibition of upper airway neural and muscle activity, and suppression of protective arousal responses. These processes tend to narrow the airway lumen. Originally the upper airway narrowing associated with sedation was attributed to a posterior shift of the base of the tongue. Evidence now suggests that the soft palate and, to a lesser extent, the epiglottis are more relevant.

References available on request

Practical Awake Flexible/Fibreoptic Intubation

Dr Brigid Brennan
Department of Anaesthesia
University of Cape Town

Awake fibreoptic intubation is an essential skill in the management of the patient with a known or suspected difficult airway. Despite technical advances in the field of airway management with new devices being added to the arsenal almost daily, AFOI remains the gold standard for the management of the anticipated difficult airway without airway obstruction. This should be seen as a core skill for which competence should be gained during your registrar time. It is our responsibility as 'airway experts' to ensure that we have the necessary skills to perform an AFOI safely. The single most common cause of a failed FOI is lack of experience and training.

Airway assessment continues to be an imperfect science but should be performed in every patient preoperatively to reduce the risk of patient harm. A strategy for airway management that preserves patient oxygenation and ventilation throughout the perioperative period should be used for every patient. The most recent version of the ASA guidelines for management of the difficult airway was published in 2013. (Appendix 1). Note the position of the awake fibreoptic intubation in the algorithm. In these guidelines there is no role for the fibreoptic bronchoscope if laryngoscopy and mask ventilation are impossible after induction of general anaesthesia. Unfortunately there is just not enough data to support every recommendation made concerning airway management, in the absence of hard evidence expert opinion and group consensus may fill the gaps.

The Fourth National Audit Project of the Royal College of Anaesthetists (NAP4) highlighted the underuse of AFOI in the management of difficult airways as well as a number of factors leading to its failure including lack of experience, inappropriate sedation, inability to view landmarks and endotracheal tube impingement during railroading. The audit identified numerous cases in which awake intubation with a flexible bronchoscope was indicated but was not used. Poor planning contributes to poor airway outcomes. It is also important to plan for failure of your primary airway plan.¹

Advantages of the awake state for flexible fibreoptic intubation

Spontaneous ventilation maintained
Oxygenation and ventilation maintained
Anatomy and muscle tone preserved, intubation therefore easier
Airway protection preserved
Safety
Options preserved

Definition of a difficult airway

ASA: A clinical situation in which a conventionally trained anaesthetist experiences difficulty with facemask ventilation, supraglottic device ventilation, tracheal intubation or all three. A more complete definition would include difficulty with tracheal access and a consideration of the airway at extubation.

Difficult intubation has been defined as outright failure, Cormack and Lehane grade 3 or 4 laryngoscopy, the need to use specialist equipment or more than 2 attempts at intubation. There is a lack of consensus for these definitions.

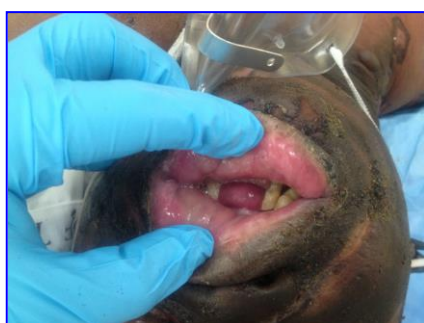Indications

The main indication for an awake intubation is a suspected or known difficult airway. In a case of easy mask ventilation but isolated difficulty with tracheal intubation, an asleep technique may be appropriate. The role of AFOI in a partially obstructed airway continues to be debated.

Another indication is to avoid iatrogenic injury e.g. a patient with an unstable C-spine. The overall incidence of secondary cervical injury attributable to intubation is very small. In an observational study of 327 patients with cervical spine disease, 39% were intubated with AFOI. Anaesthetists were more likely to use this technique if the patient had myelopathy, unstable or fractured vertebrae, or spinal canal stenosis. There is no published data to suggest that AFOI improves outcome in cervical spine injured patients compared to other intubation methods.⁶

Indications:

Suspected or known difficult airway
Anticipated difficult laryngoscopy and tracheal intubation
Anticipated difficult mask ventilation
Anticipated difficult rescue technique
Avoidance of iatrogenic injury e.g. unstable C-spine



Contra-indications:

Absolute:
Patient refusal or non-compliance
Relative:
Lack of skill/equipment
Critical airway obstruction
Contamination upper airway
Grossly distorted anatomy
Local anaesthetic allergy
Penetrating eye injury
??Aspiration risk
Nasal route: Fractured base of skull
Coagulopathy

The difficult airway with impending airway obstruction

AFOI can be successful when done by experts in selected cases, depending on the site of obstruction and with nasendoscopy and radiological investigations to aid decision making. However, AFOI can also precipitate complete airway obstruction in this scenario. On the topic of the management of the obstructed airway I refer you to an article published in Anaesthesia 2011 titled "Progress in the management of the Obstructed Airway⁹". Successful use of an AFOI technique for an obstructed airway requires skill, an understanding of the nature and level or site of obstruction and recognition that with advanced glottic obstruction, fiberoptic techniques fail.

Patients at risk of aspiration

Some debate exists about the use of airway topicalisation and AFOI in these patients but numerous reports of its success exist when relevant precautions are taken, e.g. aspiration prophylaxis, sitting /semi sitting patient position. In patients at risk of aspiration it may be best to avoid the transtracheal and possibly superior laryngeal nerve blocks. A spray-as-you-go technique might be safer. Postoperative oral intake should only be allowed once cough and swallowing reflex have returned to normal.

Requirements for AFOI

It is essential to have a working knowledge of the anatomy of the normal upper and lower airways, from the nasal passage to the bifurcation at the carina. It is also important to know the mechanism of action and maximum doses of various local anaesthetics and vasoconstrictors used. Most importantly the anaesthetist must have a management plan A, B, C...

The flexible bronchoscope

There are 2 types of flexible bronchoscopes, a fibreoptic bronchoscope and a video bronchoscope. Be familiar with your device. The fibreoptic scope contains bundles of optical fibres each with a diameter of 8-25µm that transmit the image, a different group of fibres that transmit light to the distal end and cables from a control lever in the handpiece. The hollow channel can be used for aspiration of secretions or installation of local anaesthetic. The image can be displayed on a monitor by attaching a camera to the eyepiece. A video bronchoscope has a distal video chip from which the image is transmitted electronically to a video display.

The scope can be maneuvered in three planes: Tip flexion-extension, rotation of entire scope, advance-withdrawal of entire scope. The external portion of the scope should be kept as straight as possible during manipulation so that rotation of the hand piece is transmitted to the distal end.

Use the dominant hand to perform the finer movements of aiming the tip in the correct direction, rotating the tip and advancing/withdrawing the scope. Move the control lever and depress the suction valve with the non-dominant hand.²

Difficulty passing the tracheal tube over a correctly positioned scope is a common problem. The most common sites for hold up of the ETT are the inter-arytenoid notch and the right arytenoid cartilage and epiglottis. Hold up of the ETT is more likely if there is a significant size discrepancy between the diameter of the scope and the ETT. Try to advance the ETT through the cords with the bevel facing posteriorly. If hold up occurs withdraw the tube 1-2cm, rotate 90° anticlockwise and advance again. Never force the ETT. An alternative is to use a special ETT with a soft tapered end, e.g. the ETT of an intubating LMA.

Nasal vs oral intubation

The type of surgery may dictate which route is chosen.

The nasal route is technically easier as there is a less acute angle to negotiate with the bronchoscope in the nasopharynx and on extubation a nasal tube is better tolerated and can be left in as a nasopharyngeal airway.

The Berman and Ovassapian airways are devices that facilitate the passage of a fibreoptic scope and endotracheal tube through the mouth into the oropharynx. Measure the distance from the corner of the mouth to the ear, this should be equal to the distance from the mouth opening to the glottis.

Airway Innervation

Nasal cavity

Anterior third of nasal septum and the nares are innervated by the ethmoidal nerve, a branch of the olfactory nerve (CN 1). The posterior cavity is innervated by branches of the maxillary nerve (trigeminal nerve). Specifically the greater and lesser palatine nerves from the pterygopalatine ganglion innervate the turbinates and most of the nasal septum. The pterygopalatine ganglion is located posterior to the middle turbinate in the pterygopalatine fossa. .

Oropharynx

The oropharynx is mainly innervated by the glossopharyngeal nerve with both motor and sensory fibres. It enters the pharynx between the superior and middle constrictor muscles of the pharynx and provides sensory fibres to the posterior third of the tongue, vallecula, anterior surface epiglottis, walls of pharynx and tonsils.

Larynx

Branches of the vagus nerve innervate the larynx and trachea. The Internal branch of the superior laryngeal nerve provides sensation to vocal cords, posterior epiglottis, arytenoids and aryepiglottic folds. Essentially it is the sensory supply to the larynx above the vocal cords. It originates from the superior laryngeal nerve lateral to the greater cornu of the hyoid bone.

The recurrent laryngeal nerve is the sensory supply to the vocal cords and below, as well as motor function of all intrinsic laryngeal muscles except cricothyroid which is innervated by the external branch of the superior laryngeal nerve.

Anaesthetising the airway

The aim here is to reduce sensation over specific regions that will be encountered by the scope and ETT and so reduce undesirable elevations in the patient's sympathetic and parasympathetic outflow as well as improve operator success.

There are many safe and effective ways of achieving suitable airway anaesthesia. Whichever method is chosen, adequate airway anaesthesia is the key to a successful awake intubation and should not be rushed.

Some techniques of airway anaesthesia

Nebulizers: Entire airway

Topical sprays and gels: Upper airway

Spray-as-you-go: Larynx and trachea

Transtracheal injection: Larynx and trachea

Nerve blocks: Distribution of nerve supply

Combinations of the above

Miller's Anaesthesia, 7th Edition.

Topical anaesthesia

Topicalisation of the airway involves spreading of local anaesthetic over a region of the mucosa to achieve local uptake and neural block of that region. Adequate time allocation is needed to provide optimal conditions. Topical anaesthesia reduces the calibre of a normal airway. Topicalising the airway in a patient with critical airway narrowing can lead to complete airway obstruction and should only be performed by experts when there is a team ready to perform an immediate surgical airway.

Lignocaine is the most widely used agent for topical airway anaesthesia as it has a favourable safety profile. It is available in a variety of concentrations and can be combined with a vasoconstrictor such as adrenalin or phenylephrine. The vasoconstrictor decreases local blood flow, slows the rate of absorption of local anaesthetic and prolongs its effect.

The use of cocaine has largely fallen out of favour in this setting. It has marked sympathomimetic activity and may cause cardiac dysrhythmias and myocardial ischaemia. (Maximum dose for topical anaesthesia is 1.5mg/kg.)

The maximum described dose for topical administration of lignocaine is 9mg/kg lean body mass in adults, with or without adrenalin, although this high a dose is seldom necessary. Calculate the maximum dose for your patient and do not exceed that. It is important to take note of further local anaesthetic that may then be used by the surgeon. Lignocaine has a narrow therapeutic range with toxicity being dose related and proportional to plasma levels. The accepted plasma threshold before signs of toxicity are seen is 5mg/L. However, factors such as hyperaemia and oedema of the airway caused by infection/trauma/tumour can enhance transmucosal systemic absorption of local anaesthetic. Hypercarbia and hepatic dysfunction can also facilitate the onset of neurotoxicity with

serum concentrations lower than 5mg/L. Care should be taken in such patients and a lower total dose used. About 25% of the dose of lignocaine given is absorbed. Most of the lignocaine administered via sprays or gels is swallowed and undergoes first pass hepatic metabolism.

Lignocaine 2-4% should be used. A quicker and denser block can be achieved with a 4% solution.

Lignocaine can be nebulised, administered as a spray-as-you-go technique (SAYGO), gargled, via soaked pledgets judiciously placed or by airway blocks.

With nebulised lignocaine the density of anaesthesia throughout the airway may be variable and so this technique may need to be supplemented by a spray-as-you-go approach.

Spray-as-you-go technique allows supplementation of topicalisation as you advance the scope. It is particularly useful at the cords and below (recurrent laryngeal nerve). It does cause coughing and requires time for recovery after each application. Use an epidural catheter (cut off multihole tip) down side port of scope and advance until visible beyond scope, inject 1-2ml 4% lignocaine above and below the cords. Alternatively put 2 ml of 4% lignocaine in a 10ml syringe, fill the rest with air and inject directly via suction port of scope rapidly onto the vocal cords.

Lignocaine soaked swabs or cotton pledgets can be left for 5-15 minutes in the regions of mucosa that require anaesthesia e.g. nasal passages. Add adrenaline 1:200 000 or phenylephrine (0.05%). Alternatively use a vasoconstricting nasal spray (oxymetazoline) before applying the local anaesthetic.

Various other preparations include remicaine jelly to the nostrils with a pus swab, benzocaine oily foam via long spray nozzle, benzocaine lozenges, xylocaine spray (each activation of metered dose delivers 10mg lignocaine), amongst others.

Airway nerve blocks¹⁰

Nerve blocks produce more profound and longer lasting anaesthesia than topical anaesthesia, however they are invasive, must be performed bilaterally and can be quite unpleasant for the patient.

Nose: Lignocaine soaked swabs to nose.

Oropharynx: Glossopharyngeal nerve block will block the gag reflex and facilitate the passage of the ETT through the posterior pharynx. It can be blocked most easily as it crosses the palatoglossal arch. It can be blocked by topical spray, direct mucosal contact of soaked pledgets in the tonsillar fossa or by injection infiltration.

Intraoral or extraoral approach

Intraoral: Anaesthetise tongue with topical anaesthetic. 22G needle. 5ml 2% lignocaine submucosally at the caudal aspect of the posterior tonsillar pillar (palatopharyngeal fold).

Extraoral: Peristyloid approach. With the patient supine draw a line from angle of the mandible to the mastoid process. Using deep pressure, palpate the styloid process just posterior to the angle of the jaw along this line. Use a short, small gauge needle and seat it on this process. Withdraw needle and direct posteriorly off the styloid process. As soon as bony contact lost 5-7ml 2% lignocaine injected after careful aspiration.

Both intra and extra oral approaches involve deposition of local anaesthetic close to the carotid arteries. The palatoglossal arch is a highly vascular area and so accidental vascular injection is an ever present risk. Significant absorption of the local anaesthetic can also be expected in this region. As with any injection in a highly vascular region this may be contraindicated in patients with coagulopathies or on anticoagulation medication.

Larynx: Superior laryngeal nerve block: The internal branch arises from the superior laryngeal nerve lateral to the greater cornu of the hyoid bone. The nerve should pass 2-4mm inferior to the greater cornu of the hyoid bone, from here it pierces the thyrohyoid membrane and travels under the mucosa in the pyriform recess.

Blockade of this nerve can be done by bilateral injections at the level of the greater cornu of the hyoid bone. Patient supine, head fully extended. Cornu of hyoid bone located below angle of mandible. Palpate outward from the thyroid notch along upper border of thyroid cartilage until greater cornu is encountered just superior to its posterolateral margin. Nondominant hand displaces hyoid bone with contralateral pressure bringing ipsilateral cornu and internal branch of superior laryngeal nerve toward anaesthetist. 25G inserted anteroinferomedial direction until lateral aspect greater cornu contacted. Needle walked off inferior border of greater cornu, thyrohyoid pierced and internal branch blocked. If needle retracted slightly after contacting hyoid bone both internal and external branches are blocked. 2ml lignocaine injected after aspiration.

If the patient is unwilling or unable to tolerate these injections due to distorted anatomy for example, soaked pledgets with right angle forceps can be placed in the pyriform fossa on either side of the root of the tongue for 5-10 minutes.

Recurrent laryngeal nerve block: The transtracheal block will prevent coughing as the endotracheal tube passes through the vocal cords.

Transtracheal block: Cricothyroid membrane located in midline. Small skin wheal of local anaesthetic. 22G needle on 10ml syringe with 4ml 4% lignocaine (or butterfly needle) passed perpendicular to trachea. Needle is advanced with continuous aspiration until air is aspirated. Rapidly inject on end expiration. The resultant coughing on injection of the LA disperses the LA solution and blocks sensory branches of recurrent laryngeal nerve. Motor function is unaffected. This block can be done with a needle cannula and the cannula left in situ for rescue oxygenation and to provide a conduit for the passage of a guidewire for seldinger tracheostomy, potential retrograde intubation or cricothyroidotomy.

Alternatively a spray-as-you-go technique with an epidural catheter down the side port of the fiberoptic scope can block this nerve.

Structure	Nerve	Nerve Block
Nose	Ethmoidal nerve Maxillary nerve	Lignocaine soaked pledgets
Oropharynx	Glossopharyngeal nerve	Intraoral palatopharyngeal fold Extraoral peristyloid approach
Larynx	Superior laryngeal nerve, internal branch Recurrent laryngeal nerve	Greater cornu hyoid bone Transtracheal injection

Antisialagogue

Oral secretions can make visualisation difficult and serve as a barrier to effective penetration of the local anaesthetic into the mucosa. Glycopyrrolate 3-4ug/kg ivi 30 minutes preoperatively or atropine 0.5-1mg IM/IVI.

Sedation

Awake intubation can be achieved using local anaesthesia alone but sedation is often required to improve patient tolerance. The safety of AFOI lies in the ability to maintain spontaneous ventilation and the ability to stop and perform a different technique if intubation is unsuccessful. The use of sedation is generally accepted in a non-obstructed airway. Some argue that it should not be used as it is essential to maintain lower airway reflexes to avoid aspiration. It does however assist with patient compliance and so improves the chances of a successful intubation.

It is not easy to strike the balance between patient comfort and good intubating conditions on the one hand and maintaining spontaneous ventilation and a patent airway on the other. Oversedation can cause airway obstruction, respiratory depression, or apnoea which can result in significant morbidity or mortality (NAP4).

In order to provide safe sedation the following should be adhered to:

Patient selection: It has been said that sedation should not be used in a patient with airway obstruction or respiratory failure. The emergence of newer therapies may challenge this view.

Drug selection: The appropriate choice of drug(s) for the patient and the pathology.

Sedationist: If sedation is used for an AFOI a second anaesthetist must be present and be responsible for administering and monitoring the effects of sedation.

The goals of sedation for an AFOI would be a co-operative patient, maintaining his own airway with minimal respiratory depression.

Due to the relatively small numbers of AFOI performed, and the variable pathologies for which it is indicated, there are relatively few well designed RCT's comparing different sedation regimes/drugs.

A recent review of the literature on this topic was published by *Can J Anaesth* 2013⁴. This looked at the evidence supporting the use of agents with regard to their efficacy, recommended doses, techniques and limitations to their use for AFOI. Benzodiazepines, opioids, propofol, alpha-2 agonists and ketamine have all been described to facilitate AFOI. From this review it appears there is good evidence to support the use of remifentanyl and dexmedetomidine in particular.

A lot of these studies looked at patient recall of events as an indicator of drug efficacy. In this author's opinion recall is part of the definition of an AFOI. Ideally the recall should not be distressing but I do not think amnesia/hypnosis should be a primary target of the sedation regime used.

The ideal sedative for AFOI would provide anxiolysis, have analgesic properties, suppress the cough and gag reflex, be safe and easy to titrate with minimal respiratory and cardiovascular side effects, and have an antidote.

Drugs that are most suitable have both anxiolytic and analgesic properties and would ideally not depress ventilation. The ideal choice may vary depending on patient and pathology. For example the conditions for safe intubation of a patient with an oropharyngeal mass and respiratory distress are very different from those required for the management of a patient with an unstable cervical spine injury in whom coughing and straining should be avoided.

Psychological preparation of the patient is vital and contributes hugely to anxiolysis but this is sometimes not enough. The analgesic effects supplement local anaesthesia and may limit respiratory and cardiovascular responses to airway instrumentation.

The use of a combination of drugs during AFOI can result in synergistic or antagonistic effects between the drugs used. The effect of this could be over/undersedation as well as respiratory depression which could compromise the safety of the technique. While synergism may be desirable it can be unpredictable.

Benzodiazepines

Midazolam is commonly used in combination with an opioid for AFOI. It might well be one of the most commonly used sedatives for AFOI. However a review of the literature with only a small number of studies available makes it difficult to arrive at a conclusion on its use. The advantages would be its wide availability, availability of an antidote (flumazenil) and user experience with the drug. However, a major disadvantage is the risk of oversedation with bolus injections and the wide inter-patient variability in response to the drug.¹²

Propofol

Most studies using propofol use it as a TCI technique with or without remifentanyl.

3 RCT's compared propofol with remifentanyl and 1 RCT compared it with dexmedetomidine.

In all of these trials Remi/Dex was superior to propofol in terms of intubating conditions. The only benefit of propofol seems to be decreased recall. All of these trials show that the balance between underdosing (coughing and straining) and overdosing (airway obstruction and loss of co-operation)

can be difficult to achieve. The use of propofol for AFOI is associated with a low incidence of recall at the expense of an increased risk of oversedation.

Propofol is definitely unsuitable for sedation for AFOI if airway topicalisation is not used. There is no clear consensus on the dose range, however it does seem that the risk of oversedation increases with effect site concentrations greater than 3 ug/ml.

More recently case reports have described the use of propofol with remifentanyl. The dose ranges used are TCI propofol Cet 0.8-2.0 ug/ml and remifentanyl 1.5-3.2 ng/ml. Although there is no evidence to support the use of TCI propofol over fixed rate infusion it is safe to say that TCI has a more consistent pharmacodynamic effect and may allow for a more predictable level of sedation.

Opioids

AFOI can cause intense nociceptive stimulation especially during passage of the endotracheal tube through the nose and larynx. Opioids can help to attenuate the coughing and haemodynamic changes associated with airway instrumentation. In situations where local anaesthesia may be inadequate e.g. mucosal inflammation, difficult anatomy, excessive secretions, opioids may be beneficial. In the history of AFOI most opioids have been administered as boluses. It must be noted that boluses of opioids combined with midazolam for sedation can result in significant hypoxaemia, apnoea and aspiration.

Remifentanyl

Remifentanyl is a potent, ultra-short acting synthetic μ -opioid receptor agonist with a context sensitive half-time of 3 minutes and an elimination half-time of 6 minutes. It is metabolised by nonspecific plasma and tissue esterases. This makes it easy to titrate while providing profound analgesia and suppression of airway reflexes with little effect on cognitive function.

Initial studies used remifentanyl as a fixed rate infusion in ug/kg/min. Even at doses of 0.25-0.5ug/kg/min where respiratory depression was common, it was always correctable by verbal commands to breathe. Further studies have shown that manual administration of remifentanyl is more likely to be associated with overshoot, interpatient variability and accumulation than effect site targeting with TCI models. There is evidence to suggest that remifentanyl administered by TCI is associated with a lower incidence of complications (apnoea, respiratory depression) compared with manual administration.

In the 3 RCT's comparing propofol to remifentanyl all remifentanyl patients were able to open their eyes and breathe on command if saturations fell; this was not the case in the propofol group.

The dose range for TCI remifentanyl for AFOI is Cet 3-5ng/ml when used with midazolam 1-2mg or when combined with a small effect site concentration of propofol <1ug/ml. With adequate topicalisation and counselling of the patient remifentanyl alone at <3ng/ml titrated to effect may be adequate.

3 studies have looked at the use of remifentanyl for AFOI without topicalisation or any other sedation. Obviously the dose ranges here were much higher to achieve suitable intubating conditions. Cet 6-8ng/ml.

Remifentanyl is commonly used in combination with propofol in order to reduce the high incidence of recall. However patients who do have recall when remifentanyl is used alone don't describe the recall as unpleasant.

Dexmedetomidine

Dexmedetomidine is a highly selective alpha-2 agonist. It has numerous favourable characteristics for AFOI: It has sedative, antisialogogue and anxiolytic properties as well as moderate analgesic properties without having any respiratory depressant effect. In one study healthy volunteers were sedated to a degree that they were non-responsive to shaking and shouting but they still maintained spontaneous respiration.

Level 1 evidence for the efficacy and safety of dexmedetomidine for AFOI is provided by 5 RCT's. It provides good intubating conditions, high patient tolerance and high reported patient satisfaction. There is no evidence though in the form of well-designed randomised control trials demonstrating any clear benefit over remifentanil.

A Cochrane review on the use of dexmedetomidine for AFOI is awaiting further well designed randomised control trials.

Dose: 1ug/kg slow bolus over 10 minutes. Followed by an infusion 0.3-0.7ug/kg/hr. The time to onset of the sedative effect is 10-15 minutes if a loading dose is used. The full sedative effect is seen in 20-30 minutes. Dexmedetomidine has a rapid distribution phase with a half-life of about 6 minutes. It has a terminal elimination half-life of 2 hours.

The main adverse effects are hypotension and bradycardia. Bradycardia is clinically not usually a problem provided the loading dose is administered over the recommended 10 minutes. There can be an initial transient hypertensive response with the loading dose followed by hypotension. Hypotension may be a problem after induction of general anaesthesia but it should respond to boluses of a vasopressor.

The real advantage of dexmedetomidine may be seen when presented with a patient at risk of airway obstruction or respiratory failure. The use of sedation in a patient with impending airway obstruction is controversial. Avoidance of drugs that depress consciousness level and ventilatory drive is recommended. However, application of topical anaesthesia can also precipitate complete airway obstruction. There are no case reports to support the use of remifentanil in this situation but there is some evidence in case reports to support the use of dexmedetomidine.

Conclusion on sedation

The benefits of sedation during AFOI are now widely accepted and include a greater success rate and ease of intubation as well as blunting of the haemodynamic response to intubation and an improved experience for the patient. The ideal drug would be predictable, short acting, titratable and reversible. It is still essential to have psychologically prepared the patient for the procedure with appropriate counselling and if possible to maintain verbal contact with the patient during the procedure.

The introduction of drugs such as remifentanil and dexmedetomidine, with unique pharmacokinetic properties as well as the availability of TCI infusion systems which allow for easy titration and maintenance of steady state drug levels, have made the prospect of sedation for AFOI safer. However, whether or not to use sedation, and which drug(s) to use should be decided based on patient and pathology features. A second anaesthetist 'sedationist' should be present to monitor and titrate the level of sedation.

There is enough level 1 evidence in the form of well-designed RCT's to support the statement that propofol is not very effective as a primary sedative agent for AFOI. Avoidance of benzodiazepines reduces the potential for pharmacodynamic interactions between drugs, so minimising adverse effects such as respiratory depression. At this point in time the literature supports the use of 2 drugs, remifentanil and dexmedetomidine, for sedation for AFOI.

Can J Anaesth 2013⁴

Table 4 Properties and adverse effects of remifentanil, dexmedetomidine, and propofol when used for conscious sedation for AFOI

	Remifentanil	Dexmedetomidine	Propofol
Patient satisfaction	High ^{10-12,28}	High ^{13,43-45}	High ^{9-11,13}
Recall of events	High ^{10-12,25,28,29}	Variable ^{29,45,48,50}	Low ¹⁰⁻¹³
Risk of oversedation	Low ^{10-12,29,33,35,36}	Low ^{13,29,38,55,56}	High ¹¹⁻¹³
Airway obstruction	No ^{10,25,27}	No ^{13,27}	Yes ¹¹⁻¹³
Bradycardia	No ^{10-12,25,36}	Yes ^{44,50,61}	No ⁹⁻¹³
Hypotension	No ^{10-12,25,36}	Yes ^{44,50,51,61}	No ⁹⁻¹³
Respiratory depression	Yes ^{25,28,29,36}	No ^{13,29,38,46,49,50,52}	No ^{8,10-13}
Coughing	No ^{10,25}	Variable ^{13,45,48}	Yes ^{10,11,13}

AFOI = awake fiberoptic intubation

Supplemental oxygen

The use of supplemental oxygen may be advocated in cases of critical airway obstruction either via nasal prongs or an upside down face mask over the mouth to provide a safety barrier for the rare time when awake intubation precipitates complete airway obstruction. However if this is a concern perhaps an awake tracheotomy would be the preferred choice of airway management. Be aware of the danger of using supplemental oxygen when using a sedative that can suppress respiration e.g. remifentanyl, as the patient may be hypoventilating or apnoeic while maintaining oxygen saturations and becoming increasingly hypercapnoeic. When using remifentanyl this author prefers not to use supplemental oxygen and rather rely on patient saturations as a warning to encourage the patient to breathe.

Complications of AFOI

Complications of AFOI include failure, bleeding, complete airway obstruction and oversedation. Laryngeal trauma and arytenoid dislocation is more common with multiple attempts and the use of force to pass the ETT through the cords. Local anaesthetic toxicity can also occur.

Training

Complications arising from airway management are an important cause of anaesthesia associated morbidity and mortality, and although they are not common, the outcomes are often severe, in the form of either hypoxic brain injury or death. Many training programmes don't offer a structured airway management programme and many trainees probably enter practice with limited skills to deal with difficult airways. A survey of delegates at the Group of Anaesthetists in Training (UK) meeting showed that although most felt that AFOI was a core skill, the majority of final year trainees failed to reach their minimum estimated competency target of 10 intubations. It has been shown that the time to complete FOI successfully by novice residents after only 10 patients each was in the region of 1.5min.

A stepwise approach to training would be as follows⁷:

Manikins: Manikins and simulators provide a safe validated introduction to the use of fiberoptic scopes and as little as 2-4hrs of manikin training has been shown to provide adequate scope skills to enable tracheal intubation in patients.

Asleep fiberoptic intubation with predicted normal anatomy.

Awake fiberoptic intubation with predicted normal anatomy.

Awake fiberoptic intubation with predicted abnormal anatomy.

Competence should be demonstrated at each stage before progressing to the next stage.

A needle-free technique for nasal AFOI

Requirements:

Knowledge of indications and limitations of procedure.

Adequate equipment and skill available to perform the procedure.

Have an airway plan A, B, C....

Be patient! A properly conducted AFOI takes time.

Counsel and consent patient. Psychological preparation is essential.

As the patient arrives in the induction room, insert IVI and administer glycopyrrolate 3-4ug/kg.

Prepare 4% lignocaine and calculate the maximum dose for the patient (9mg/kg).

Identify most patent nasal passage. Administer oxymetazoline vasoconstricting nose drops to both nostrils.

Nebulise 4 ml 4% lignocaine with 0.5-1mg 1:1000 adrenalin.

On completion of nebulised lignocaine, use remicaine jelly on a pus swab or lignocaine soaked pledgets (with 1:200000 adrenalin) into nasal cavity and posterior nasal space.

Allow patient to gargle with 1-2ml 4% lignocaine if possible.

Consider transtracheal injection.

Take patient into operating theatre and apply standard monitoring. Have drugs for GA drawn up.

Operating table as low as possible. Position patient semi sitting or supine with anaesthetist in front of or behind patient depending on operator preference/patient convenience. Facing patient inverts FOI view.

Check scope, orientation, black notch at 12 o'clock, clear focus on written object, working suction, second wall suction with yankauer for oropharynx if needed. Prepare epidural catheter for SAYGO.

Decide on sedative: Remifentanyl 1-3ng/ml TCI or dexmedetomidine 1ug/kg over 10 minutes then 0.3-0.7ug/kg/hr. Second sedationist present.

(Supplemental oxygen if indicated via nasal prongs or face mask.)

Mount the tracheal tube on the scope for the nasal route or within the oral airway for the oral route.

Use a 6-6.5mm warmed reinforced ETT with adequate lubrication between the scope and ETT and around tip/cuff of ETT for passage through the nose. (Alternatively use ETT from intubating LMA with tapered tip to avoid hold up at arytenoids). Secure ETT to top of scope with a piece of tape or elastic band that can be easily removed.

Pass scope along floor of nasal cavity directed inferiorly behind soft palate. Identify the nasal septum medially, turbinates laterally. Keep black hole (air cavity) in centre. Patient can assist in opening the airway by protruding tongue or deep inspiration. Pink out: mucosa (no cavity); white out: secretions; red out: blood. Suction or withdraw scope and reorientate.

Targets: Epiglottis, vocal cords, tracheal cartilages, carina.

Next landmark is epiglottis, advance scope into laryngeal opening, identify vocal cords and administer SAYGO lignocaine. Warn patient they may cough. Wait. Pass epidural catheter through the cords and administer further spray-as-you-go lignocaine. Advance scope into subglottic space and identify the tracheal rings.

Advance scope until see carina.

Advance ETT with gentle pressure and rotation, bevel laterally through nose (facing turbinates) and posteriorly through cords (facing arytenoids). Ask patient to inhale deeply just before you go through the cords. Do not force ETT, if resistance withdraw ETT rotate through 90° anticlockwise and advance gently. Keep carina in field of vision at all times.

Once ETT in trachea, remove scope and connect breathing circuit. Confirm ETT position with capnography, misting, auscultation. If concern about stability of cervical spine, assess neurology at this point. Induce anaesthesia with inhalational/IVI induction agent.

Inflate cuff after induction (intensely stimulating).

Confirm ETT placement with capnography and recheck position of ETT above carina.

Extubate awake with all equipment available for reintubation.

If fiberoptic intubation is not successful, options are preserved. Surgery can be postponed and an unhurried surgical airway can be performed.

The keys to success in AFOI include good topical anaesthesia, an excellent rapport with the patient, skill and patience.

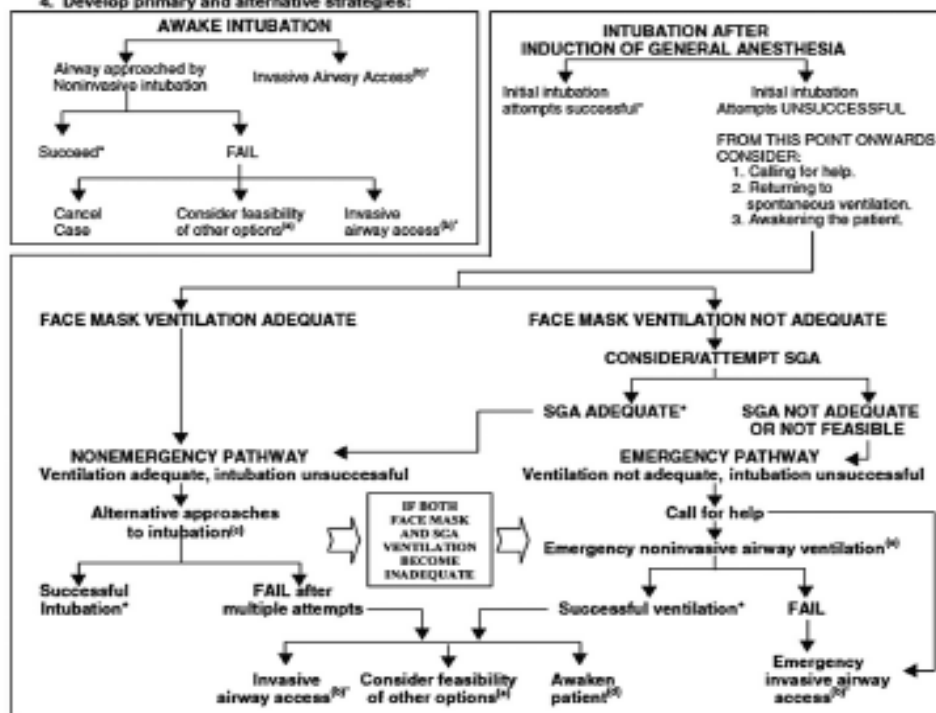
References for this section

1. Anderson J, Klock PA. Airway Management. *Anesthesiology Clin* 32 (2014) 445-461.
2. Gil K. Fibre-Optic Intubation: Tips from the ASA workshop. *Anesthesiology news guide to airway management* 2009.
3. Henderson J. Airway management in the Adult. *Miller's Anesthesia 7th Edition*. Chapter 50.
4. Johnston KD, Rai MR. Conscious sedation for awake fiberoptic intubation: a review of the literature. *Can J Anaesth* 2013; 60:584-99
5. Kritzinger S. Awake Fiberoptic Intubation – the basics. *Anaesthesia Tutorial of the Week* 201. 2010. www.totw.anaesthesiologists.org.
6. Langford RA, Leslie K. Awake fiberoptic intubation in neurosurgery. *J Clin Neuroscience* 2009; 16: 366-372.
7. Leslie D, Stacey M. Awake Intubation. *BJA CEPD rev* 2015; 15 (2): 64-67
8. Moerman AT, Herregods LL, De Vos MM, Mortier EP, Struys MM. Manual versus target-controlled infusion remifentanyl administration in spontaneously breathing patients. *Anesth Analg* 2009; 108: 828-34.
9. Patel A, Pearce A. Progress in management of the obstructed airway. *Anaesthesia* 2011; 66 (suppl 2): 93-100.
10. Regional and Topical Anaesthesia for Endotracheal Intubation. NYSORA 2013. www.nysora.com.
11. Sudheer P, Stacey MR. Anaesthesia for awake intubation. *BJA CEPD Rev* 2003;3: 120-3
12. Vennila R, Hall A, Ali M, Bhuiyan N, Pirotta D, Raw DA. Remifentanyl as single agent to facilitate awake fiberoptic intubation in the absence of premedication. *Anaesthesia* 2011; 66: 368-72.
13. Woodall NM, Harwood RJ, Barker GL. Complications of awake fiberoptic intubation without sedation in 200 healthy anaesthetists attending a training course. *Br J Anaesth* 2008; 100: 850-5.

Appendix A – ASA Difficult Airway Algorithm

DIFFICULT AIRWAY ALGORITHM

1. Assess the likelihood and clinical impact of basic management problems:
 - Difficulty with patient cooperation or consent
 - Difficult mask ventilation
 - Difficult supraglottic airway placement
 - Difficult laryngoscopy
 - Difficult intubation
 - Difficult surgical airway access
2. Actively pursue opportunities to deliver supplemental oxygen throughout the process of difficult airway management.
3. Consider the relative merits and feasibility of basic management choices:
 - Awake intubation vs. intubation after induction of general anesthesia
 - Non-invasive technique vs. invasive techniques for the initial approach to intubation
 - Video-assisted laryngoscopy as an initial approach to intubation
 - Preservation vs. ablation of spontaneous ventilation
4. Develop primary and alternative strategies:



*Confirm ventilation, tracheal intubation, or SGA placement with exhaled CO₂.

a. Other options include (but are not limited to): surgery utilizing face mask or supraglottic airway (SGA) anesthesia (e.g., LMA, ILMA, laryngeal tube), local anesthesia infiltration or regional nerve blockade. Pursuit of these options usually implies that mask ventilation will not be problematic. Therefore, these options may be of limited value if this step in the algorithm has been reached via the Emergency Pathway.

b. Invasive airway access includes surgical or percutaneous airway, jet ventilation, and retrograde intubation.

c. Alternative difficult intubation approaches include (but are not limited to): video-assisted laryngoscopy, alternative laryngoscope blades, SGA (e.g., LMA or ILMA) as an intubation conduit (with or without fiberoptic guidance), fiberoptic intubation, intubating stylet or tube changer, light wand, and blind oral or nasal intubation.

d. Consider re-preparation of the patient for awake intubation or canceling surgery.

e. Emergency non-invasive airway ventilation consists of a SGA.

Fig. 1. The ASA difficult airway algorithm. (From Apfelbaum JL, Hagberg CA, Caplan RA, et al. Practice guidelines for management of the difficult airway: an updated report by the American Society of Anesthesiologists Task Force on Management of the Difficult Airway. *Anesthesiology* 2013;118(2):257; with permission.)

Awake Fiberoptic Intubation— Precedex® Adult Treatment Protocol

The protocol below reflects treatment with Precedex in a Phase III, randomized, multicenter, double-blind study of 105 patients with high-risk airways undergoing elective awake fiberoptic intubation.

Infuse Precedex with a controlled infusion device.

In patients already sedated with other anesthetics, sedatives, hypnotics or opioid analgesics, a Precedex loading dose may not be necessary.

Coadministration of anesthetics, sedatives, hypnotics and opioids with Precedex can enhance the pharmacodynamic effects of these agents. A reduction in the dosage of Precedex or the concomitant medication may be required.

Patients receiving Precedex may be arousable and alert when stimulated. This alone should not be considered as evidence of lack of efficacy in the absence of other clinical signs and symptoms.

Premedicate With Glycopyrrolate 0.1 mg IV
Helps minimize aspiration risk by:

- Reducing salivary, tracheobronchial and pharyngeal secretions
- Reducing volume and free acidity of gastric secretions

Glycopyrrolate can also be used intraoperatively to counteract surgical, drug-induced or vagal reflexes associated arrhythmias and protect against peripheral muscarinic effects (e.g., bradycardia and excessive secretions) of cholinergic agents.

Start Supplemental Oxygen by Nasal Cannula or Face Mask

Prepare Precedex

- Withdraw entire 2 mL contents of the Precedex vial
- Add to 48 mL of sodium chloride injection to total 50 mL
- Shake gently to mix well

Initiate Precedex Loading Dose one (1) mcg/kg over 10 min

After 10 min, Continue Precedex Maintenance Infusion at 0.7 mcg/kg/hr

Assess Sedation Level
15 min after initiating Precedex and every 3 min thereafter

Expect Moderate Decreases in BP & HR
If intervention is required, consider:

- Reducing Precedex dosage
- Discontinuing Precedex
- Administering intravenous fluid
- Elevating lower extremities
- Administering glycopyrrolate or atropine

Transient Hypertension Also May Occur
This occurs primarily during the loading infusion. Treatment has generally not been necessary, although reduction in the loading infusion rate may be desirable.

Undersedated
Ramsay Sedation Score (RSS) = 1
RSS 1 = Patient anxious and agitated or restless or both

Administer 0.5 mg midazolam as needed (maximum 0.2 mg/kg) until RSS \geq 2

Adequately Sedated
RSS 2 or more
RSS 2 = Patient cooperative, oriented and tranquil
RSS 3 = Patient responds to commands only
RSS 4 = Patient exhibits brisk response to light glabellar (between eyebrows) tap or loud auditory stimulus
RSS 5 = Patient exhibits sluggish response to light glabellar tap or loud auditory stimulus

Maintain Precedex

Apply Airway Topical Anesthesia

- Deliver nebulized 4% lidocaine (2 to 4 mL) over 10 min using a standard nebulizer with oxygen 8 to 10 L/min
- If possible, have the patient gargle with 4% viscous lidocaine (1 to 2 mL)
- For nasal intubation, place 2% lidocaine jelly (1 to 2 mL) within the nostril
- Assess sedation level (target RSS \geq 2)

Assess Topicalization

- *Oral intubation:* Stimulate the uvula, tongue and bilateral posterior pharyngopalatine fauces with a wooden tongue blade
- *Nasal intubation:* Stimulate the posterior nares at least 3 cm from the anterior os with a soft-tipped swab stick in addition to stimulating the uvula, posterior tongue and bilateral posterior pharyngopalatine fauces with a wooden tongue blade

Intubate the Patient After Adequate Topical Anesthesia, RSS \geq 2 and Absence of Gag Reflex

- Administer additional 2% lidocaine (in 1 to 2 mL aliquots) to the lower airway via the working channel of the bronchoscope
- Ask the patient to take slow, regular and deep breaths to facilitate distribution of the local anesthetic to the lower airway
- Administer 0.5 mg midazolam as needed (maximum 0.2 mg/kg) until RSS \geq 2

Safety Considerations

Hypotension and bradycardia may necessitate intervention and may be more pronounced in patients with hypovolemia, diabetes mellitus or chronic hypertension as well as in the elderly. Use with caution in patients with advanced heart block or severe ventricular dysfunction.

Please see accompanying full Prescribing Information.




www.precedex.com

Source: www.precedex.com




For more information on Advancing Wellness™, contact your Hospira representative



FIBROPTIC GUIDED TRACHEAL INTUBATION THROUGH SUPRAGLOTTIC AIRWAY DEVICE (SAD) USING AINTREE INTUBATION CATHETER


Please ensure the SAD is in place; give 100% oxygen; confirm adequate sedation/anaesthesia, ventilation & paralysis



Aintree catheter


- ◆ 56cm long hollow catheter
- ◆ 6.5mm outer diameter; 4.7mm inner diameter
- ◆ Easily preloaded onto an appropriately sized intubating fibroscope (maximum insertion cord diameter - 4.2mm)
- ◆ Flexible enough for loading over fibroscope
- ◆ Stiff enough to facilitate railroading of tracheal tube
- ◆ Comes with 2 rapid adaptors (please refer to manufacturer's guidelines)
- ◆ Used for SAD assisted orotracheal fiberoptic intubation

4




Note depth of AIC. With assistant immobilising SAD and the operator maintaining the position of AIC, the FS alone is withdrawn after removal of securing tape.

5




Briefly disconnect SAD (along with swivel connector) from anaesthetic circuit, deflate cuff (if present) and start withdrawing SAD (along with swivel connector), applying counter pressure on AIC to prevent movement. Once the SAD cuff becomes visible, grasp AIC in the mouth and fully remove SAD with the swivel connector. The process should be done with care. Again note the depth of AIC at the lips, ensuring that it never exceeds 26cm.

6



Using a laryngoscope, railroad the tracheal tube (ETT) over AIC ensuring a 'tip anterior' orientation. Use a conventional ETT - minimum size is 7.0 and pre cut to appropriate length.

7



Reconnect circuit and re-establish anaesthesia and ventilation. Confirm end-tidal CO₂. Consider FS confirmation of ETT position.

◆ This is not an airway rescue technique

◆ It should be performed in a controlled stepwise process

◆ The process is designed to provide continued ventilation/oxygenation via the SAD and swivel connector until the SAD is removed and tracheal tube is railroaded in place

◆ Oxygen can be delivered via the AIC in situations where railroading of tracheal tube is prolonged; as sitting ventilation via this route is often suboptimal (narrow diameter/lack of cuff). Refer to manufacturer's guidelines for methods of oxygen delivery.


Recommendations

1. Consider a second anaesthetist in addition to a trained assistant.
2. Use a camera system for fibroscope.

Caution


The Aintree catheter is not recommended with the LMA Supreme.

1



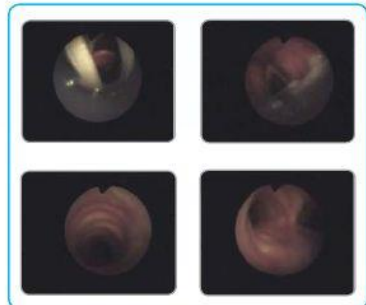
Having prepared the fibroscope (FS) and camera system, lubricate the outer surfaces of both the Aintree Intubation Catheter (AIC) and FS. Preload AIC onto FS and secure with tape. Attach a 15mm bronchoscopic swivel connector (with port) to SAD and attach the anaesthetic circuit to the swivel connector. Confirm adequate anaesthesia, muscle relaxation and assisted ventilation.

2



The SAD should be immobilised by an assistant. Introduce FS with loaded AIC through top port of swivel connector into the SAD lumen.

3



Sequentially visualise SAD aperture bars (if present), glottis, tracheal rings and finally carina as the FS passes caudally. Never advance beyond carina.

Permission for use granted by Cook Medical Incorporated, Bloomington, Indiana.

Authors: Dr. Rajmohan Padmanabhan, Consultant Anaesthetist, NHS Lanarkshire
 Dr. Barry McGuire, Consultant Anaesthetist, NHS Tayside

Illustrations produced by Andy Morris, Medical Illustration Department, NHS Lanarkshire. 24/01/2011

The AIC was invented in Liverpool, UK.
 Reference: Anaesthesia, volume 51, pages 1123-1126.

Appendix D – References

- 1 Pandit JJ, Popat MT, Cook TM, et al. The Difficult Airway Society 'ADEPT' guidance on selecting airway devices: the basis of a strategy for equipment evaluation. *Anaesthesia* 2011; **66**: 726-37
- 2 Weiss M, Engelhardt T. Proposal for the management of the unexpected difficult pediatric airway. *Paediatric anaesthesia* 2010; **20**: 454-64
- 3 Sillen A. Cognitive tool for dealing with unexpected difficult airway. *British journal of anaesthesia* 2014; **112**: 773-4
- 4 Group SAW. SASA Airway Guidelines. *SAJAA* 2014; **20**: S1-S15
- 5 Boedeker BH, Bernhagen MaB, Miller DJ, Doyle DJ. Comparison of the Magill forceps and the Boedeker (curved) intubation forceps for removal of a foreign body in a Manikin. 2012; 25-7
- 6 Suzuki A, Tampo A, Kunisawa T, Henderson J. Use of a new curved forceps for McGrath MAC video laryngoscope to remove a foreign body causing airway obstruction. *Saudi journal of anaesthesia* 2013; **7**: 360-1
- 7 Arslan ZI, Yildiz T, Baykara ZN, Solak M, Toker K. Tracheal intubation in patients with rigid collar immobilisation of the cervical spine: a comparison of Airtraq and LMA CTrach devices. *Anaesthesia* 2009; **64**: 1332-6
- 8 Dhonneur G, Ndoko SK, Yavchitz a, et al. Tracheal intubation of morbidly obese patients: LMA CTrach vs direct laryngoscopy. *British journal of anaesthesia* 2006; **97**: 742-5
- 9 Goldman AJ, Rosenblatt WH. The LMA CTrach in airway resuscitation: six case reports. *Anaesthesia* 2006; **61**: 975-7
- 10 Goldman AJ, Rosenblatt WH. Use of the fiberoptic intubating LMA-CTrach in two patients with difficult airways. *Anaesthesia* 2006; **61**: 601-3
- 11 Goldman AJ, Wender R, Rosenblatt W, Theil D. The fiberoptic Intubating LMA-CTrach: an initial device evaluation. *Anesth Analg* 2006; **103**: 508
- 12 Liu EH, Goy RW, Lim Y, Chen F-G. Success of tracheal intubation with intubating laryngeal mask airways: a randomized trial of the LMA Fastrach and LMA CTrach. *Anesthesiology* 2008; **108**: 621-6
- 13 Liu EH, Wender R, Ph D, Goldman AJ. The LMA CTrach™ in Patients with Difficult Airways. 2009: 941-3
- 14 Liu EHC, Goy RWL, Chen FG. The LMA CTrach, a new laryngeal mask airway for endotracheal intubation under vision: evaluation in 100 patients. *British journal of anaesthesia* 2006; **96**: 396-400
- 15 Malik MA, Subramaniam R, Churasia S, Maharaj CH, Harte BH, Laffey JG. Tracheal intubation in patients with cervical spine immobilization: A comparison of the Airwayscope®, LMA CTrach®, and the macintosh laryngoscopes. *British journal of anaesthesia* 2009; **102**: 654-61
- 16 Michalek P, Donaldson W, Graham C, Hinds JD. A comparison of the I-gel supraglottic airway as a conduit for tracheal intubation with the intubating laryngeal mask airway: a manikin study. *Resuscitation* 2010; **81**: 74-7
- 17 Mihai R, Blair E, Kay H, Cook TM. A quantitative review and meta-analysis of performance of non-standard laryngoscopes and rigid fibreoptic intubation aids. *Anaesthesia* 2008; **63**: 745-60
- 18 Nickel EA, Timmermann A, Roessler M, Cremer S, Russo SG. Out-of-hospital airway management with the LMA CTrach--a prospective evaluation. *Resuscitation* 2008; **79**: 212-8
- 19 Sreevathsa S, Nathan PL, John B, Danha RF, Mendonca C. Comparison of fiberoptic-guided intubation through ILMA versus intubation through LMA-CTrach. *Anaesthesia* 2008; **63**: 734-7
- 20 Timmermann A, Russo S, Graf BM. Evaluation of the CTrach--an intubating LMA with integrated fiberoptic system. *British journal of anaesthesia* 2006; **96**: 516-21
- 21 Wender R, Goldman AJ. Awake insertion of the fiberoptic intubating LMA CTrach in three morbidly obese patients with potentially difficult airways. *Anaesthesia* 2007; **62**: 948-51
- 22 Choonoo J, Hofmeyr R, Meyersveld N. Initial clinical experience with the TotalTrack VLM. SASA 2015. Durban: University of Cape Town, 2015
- 23 Hofmeyr R. State of the art: Video and optical laryngoscopy. *African Journal of Emergency Medicine* 2013; **3**: S16-S



DEPARTMENT OF
ANAESTHESIA

UNIVERSITY OF CAPE TOWN

Teleflex



OpenAirway



STORZ

KARL STORZ – ENDOSKOPE

Dräger

abbvie